



Research Article

Evaluation of Injectable Anaesthetic Drugs during Spaying in Rabbits

Saroj Kumar Yadav^{1,2*} , Mushfika Tabassum³ , Sunil Yadav⁴ , and Muhammad Ahaduzzaman⁵ 

¹ Raaz Veterinary Hospital and Research Center, Janakpur Dham, Nepal

² Arabian Oryx Sanctuary, Oman

³ Master Fellow, Department of Veterinary Medicine, University of Bologna, Italy

⁴ Master Fellow, Department of Anatomy and Histology, GaZipur Agricultural University, GaZipur, Bangladesh

⁵ Professor, Department of Medicine and Surgery, Chattogram Veterinary and Animal Sciences University, Chattogram, Bangladesh

* **Corresponding author:** Saroj Kumar Yadav, Senior Veterinary Doctor of Arabian Oryx Sanctuary, Oman. Email: shirfraz@gmail.com

ARTICLE INFO

Article History:

Received: 15/10/2025

Revised: 11/11/2025

Accepted: 02/12/2025

Published: 29/12/2025



Keywords:

Anesthesia

Ketamine

Rabbit

Spaying

Xylazine

ABSTRACT

Introduction: Spaying female rabbits may be necessary to control certain behaviors and prevent pregnancy. Since gaseous anesthesia is unavailable under field conditions, injectable anesthesia is required. The present study aimed to evaluate the efficacy of routine injectable intramuscular anesthetics, including ketamine and xylazine, during the spaying procedure in rabbits.

Materials and methods: Five female short-haired rabbits, aged 20-24 months and weighing 1.5-1.7 kilograms, were presented to the Sahidul Alam Quadari teaching veterinary hospital in Chattogram, Bangladesh. Body temperature, heart rate, and respiratory rate were measured using a thermometer and a stethoscope. The spaying procedure was conducted using aseptic techniques, administering xylazine and ketamine in a single syringe of anesthesia at dosage rates of 5 mg/kg intramuscularly (IM) and 30 mg/kg IM, respectively, for the spaying procedure.

Results: All vital parameters were within normal ranges. Injectable anesthetic xylazine at 5 mg/kg of body weight and ketamine at 30 mg/kg of body weight, administered IM, provided effective anesthesia during rabbit spaying without any complications on heart rate and respiration rate, as well as any complications during the surgery procedure. These doses were found to be optimal for field conditions.

Conclusion: The present study indicated that successful rabbit spaying can be achieved with IM anesthesia using the recommended doses of ketamine (30 mg/kg) and xylazine (5 mg/kg).

1. Introduction

Spaying, known as ovariectomy, is a surgical technique that is used to regulate the population of rabbits, especially those kept as pets indoors, which involves completely removing the uterus and ovaries in order to sterilise female animals¹. Depending on the size and growth pace, sexual maturity in rats occurs between four and eight months of age; bigger breeds, such as angora, reach sexual maturity later than smaller breeds². Ordinarily, routine spaying is performed at 5-8 months of age, although spaying can occasionally occur later³. But as rabbits get older, they gain a lot of fat in the mesometrium, which makes surgery more difficult since the veins are lodged in the uterus's wide ligament⁴. One of the most popular major abdominal procedures in veterinary medicine is spaying⁴. In sexually mature animals, the spaying is carried out under

appropriate general anesthesia using sterile operating techniques⁵. Spaying is an irreversible process that can be carried out beneath the midline or by a small incision on the left side⁶. In addition, uterine diseases such as adenocarcinoma, uterine neoplasia, mammary neoplasia, endometrial venous aneurysms, uterine hyperplasia, pyometra, hydrometra, torsion, and rupture are treated and prevented by spaying³. Spaying prevents unwanted or troublesome behaviours, including nest-building, plucking fur, faking pregnancy, territorial aggression, and sexual behavior³.

Numerous studies have demonstrated the effects of different anesthetic medications in rabbits for injectable anesthesia in clinical practice^{7,8}. A variety of intramuscular (IM) anaesthetic combinations were administered to the

Cite this paper as: Yadav SK, Tabassum M, Yadav S, and Ahaduzzaman M. Evaluation of Injectable Anaesthetic Drugs during Spaying in Rabbits. Journal of Lab Animal Research. 2025; 4(6): 63-66. DOI: 10.58803/jlar.v4i6.85



The Author(s). Published by Rovedar. This is an open-access article distributed under the terms of the Creative Commons Attribution License (<http://creativecommons.org/licenses/by/4.0>), which permits unrestricted use, distribution, and reproduction in any medium, provided the original work is properly cited.

rabbits, including xylazine and ketamine, midazolam and fentanyl, and medetomidine and ketamine⁹. The present study aimed to assess the efficacy of xylazine and ketamine anesthesia in rabbits undergoing ovariohysterectomy surgery.

2. Materials and methods

2.1. Ethical approval

Animal interactions and surgical procedures were conducted in compliance with the guidelines established by the Institutional Ethics Committee and in accordance with local laws and regulations. During the surgical procedure, appropriate measures were implemented to mitigate pain and suffering. Essential protocol clearances were obtained

from the relevant hospital authorities to perform the procedure. The surgical procedure was performed only after the owner's concerns were addressed and formal consents were obtained.

2.2. Animals

From 2022 to 2024, five female short-haired rabbits, averaging 20-24 months in age and weighing between 1.5 kg and 1.7 kg, were presented to the Teaching Veterinary Hospital, Chittagong Veterinary and Animal Sciences University (CVASU), Chittagong, Bangladesh, for spaying procedures. The critical parameters, specifically temperature, respiration rate, and heart rate, were recorded at 102°F (38.8°C), 50 breaths per minute, and 130 beats per minute, respectively. All five rabbits exhibited no signs of disease or distress (Figure 1).

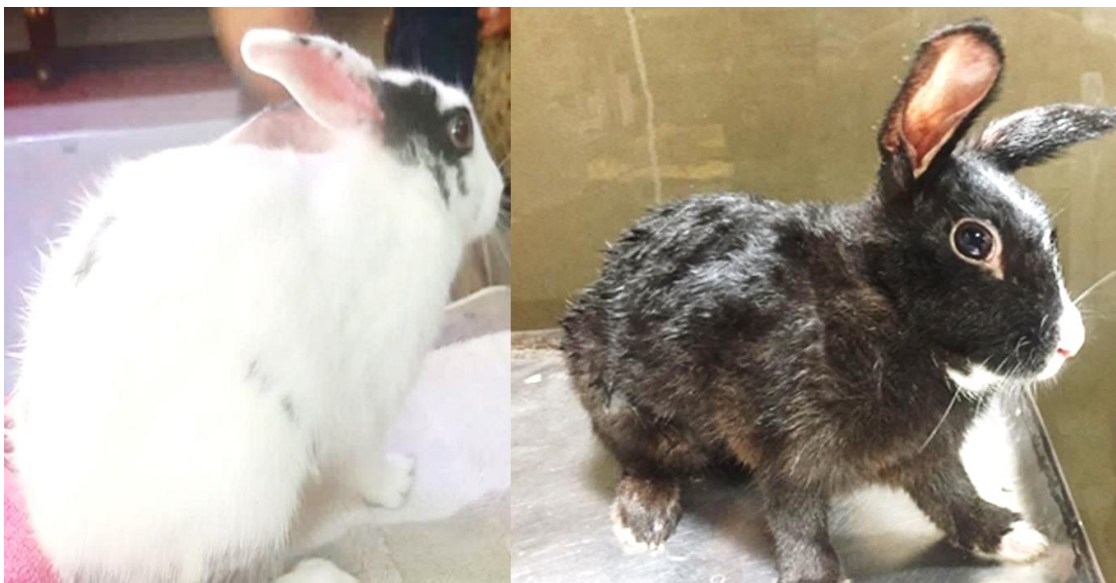

Figure 1. Healthy female short-haired rabbits, aged 20 to 24 months, with normal vital parameters before spaying

2.3. Restraining anesthesia

Under accurate and precise supervision, general anesthesia was induced with 5 mg/kg of xylazine hydrochloride, IM (Xylaxin, 2%, India Immunologicals Ltd., Hyderabad, India), and 30 mg/kg of ketamine

hydrochloride, IM (Ketalar, 50 mg/mL, Popular Pharmaceutical Ltd., Bangladesh)¹⁰. For maintenance, supplemental doses of ketamine were administered in two equal half-doses with a 20-minute interval. Table 1 shows the physiological parameters during the surgical procedure.

Table 1. Temperature, heart rate, and respiration rate of rabbits during ovariohysterectomy under general anesthesia

Anesthesia stage	Heart rate (mean)	Respiration rate (mean)	Rectal temperature (mean)
Before anesthesia	131 beats per minute	51 breaths per minute	101.5°F (38.6°C)
Right after anesthesia	151 beats per minute	57.5 breaths per minute	101.6°F (38.66°C)
Five minutes after anesthesia	157 beats per minute	60.5 breaths per minute	102°F (38.88°C)
During the surgery	120 beats per minute	42.5 breaths per minute	100.5°F (38.05°C)

2.4. Surgical procedure

For anesthesia, two injectable anesthetic drugs were used. A 0.38 mL intramuscular (IM) injection of xylazine at a dosage of 5 mg/kg was used to anesthetize the rabbit (Xylaxin®, 20 mg/mL, India Immunologicals Ltd., India). Furthermore, 0.9 mL of ketamine (G-ketamine®, 50 mg/mL, Gonoshasthaya Pharmaceuticals Ltd., Bangladesh) was administered at 30 mg/kg¹⁰. Within five minutes, all animals

fell asleep. Respiration, heart rate, and temperature were continuously tracked during the surgical procedure. The surgical procedure was adapted from the Yadav¹⁰ cesarean section procedure, with several modifications. The 7-8 cm area of the body surrounding the navel was meticulously shaved and sterilized. A 7.5% povidone-iodine (Opsonin Pharma Limited, Bangladesh) solution was used to clean the surgical site three times. The area was then sterilized twice more when the pet was moved to the surgery room, initially

with a 7.5% surgical povidone-iodine solution and again with 70% surgical alcohol. While the rabbit was under general anesthesia, the procedure was carried out under very stringent aseptic circumstances. The first step was making a 1 cm skin incision. An incision was made in the middle of the abdomen, 1 cm behind the umbilicus, during a surgical procedure. Once the linea alba was identified, the abdominal muscles were elevated using forceps, and artery forceps and gauze were used to apply compression to prevent the bleeding. After being manually palpated, the uterine horn was extracted (Figures 2A and 2B). By tracing the uterine horn to its distal extremities, the ovaries were located (Figures 2C and 2D). The cervix was maintained as

a natural barrier by ligating the arteries of the wide ligament anterior to it. The ovaries and entire uterus were then removed. To check for any indications of hemorrhage, the abdomen was checked. U-synth (2-0) sutures (Suture India Pvt. Ltd, Bangalore, India) were used to sew the muscle and peritoneum layers together in a straightforward continuous pattern for the cosmetic suture (Figures 2E and 2F). Following deep layer closure, the skin incision was left unsutured. This overall approach was considered cosmetic surgery because of its benefits in reducing postoperative adhesions and stress. After surgery, rabbits wore socks (modified clothing) to prevent licking of the surgical site and to reduce the risk of infection.

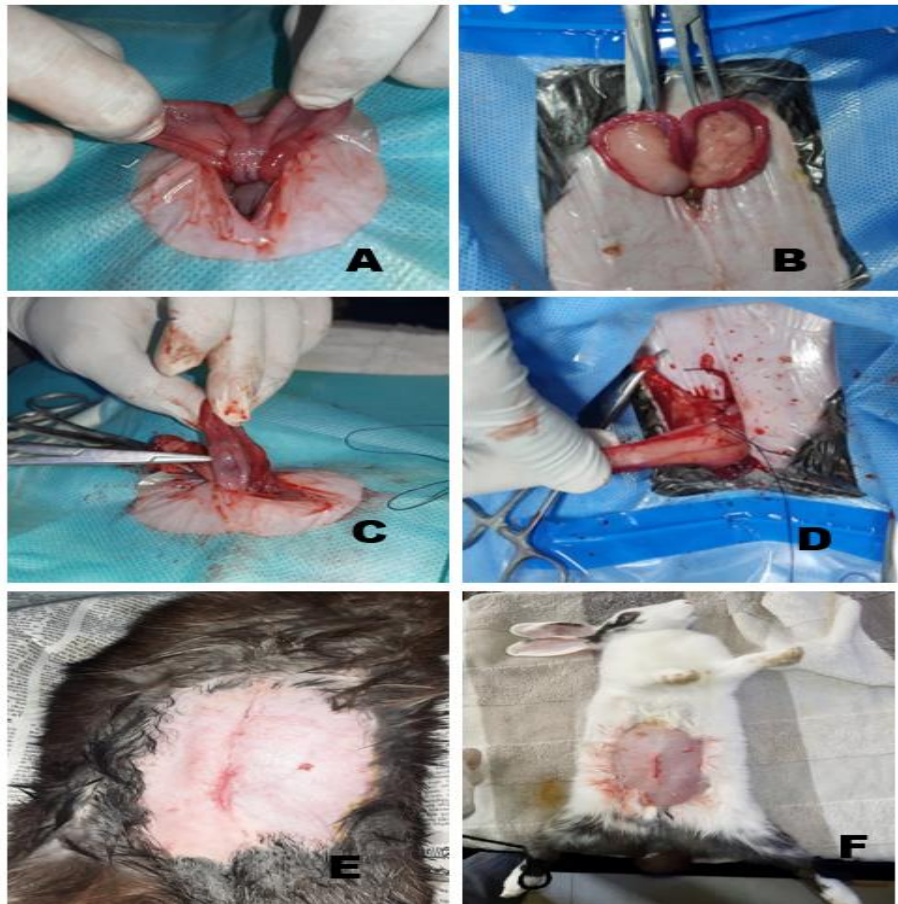


Figure 2. Spaying surgery for 20-month-old female rabbits under general anaesthesia utilising ketamine and xylazine. The surgery was carried out using the midline laparotomy incision technique. A and B: Uterus, C and D: Ovary, E and F: Cosmetic surgery.

2.5. Postoperative treatment and care

The owners were directed to wash the surgical site and apply a topical antibiotic ointment twice daily (Nebanol Plus ointment®, Square Pharmaceuticals, Bangladesh) containing neomycin sulfate, bacitracin zinc, and polymyxin B sulfate. The veterinarian administered systemic antibiotics daily for seven days, including ciprofloxacin (0.33 mL) at a dosage of 20 mg/Kg, IM, every 24 hours¹⁴ (Ciprocin 100 mg®, Square Pharmaceuticals, Bangladesh). A subcutaneous (SC) administration of the NSAID meloxicam (Melvet®, Acme Laboratories Ltd., Bangladesh) at 0.2 mg/Kg, every 24 hours¹⁰, was conducted for three

days^{15,16}. For 15 days, the rabbits were observed and monitored under the supervision of the owners and the veterinarians. No complications were observed, and the rabbit's recovery was uncomplicated. Upon confirming complete surgical site recovery after 15 days, the protective socks were removed.

3. Results and Discussion

The reproductive system of female rabbits is unique in that each uterine horn has its own cervix, which opens into the vagina, and there is no uterine body². Typically, a lateral flank approach or a ventral midline route is used to accomplish feline ovariohysterectomy¹¹. In Australia,

ventral midline incision spaying in rabbits is an established clinical practice¹², consistent with the current study, which performed the spaying using a ventral midline incision under field conditions. The ventral midline incision spaying method not only ensures a high success rate but also reduces the stress animals experience during the surgical procedure. In the present investigation, the stitches were not overly tight to prevent post-surgical adhesions, facilitating urine accumulation in the vagina while the bladder was being emptied, as supported by Varga¹³. The current investigation demonstrated that the skin was not sutured, which was considered cosmetic surgery, contrasting with the study of Richardson and Flecknell¹². After spaying, Elizabethan collars are put on, as suggested by Varga¹³, however, during the present study, socks (modified cloths) were used instead of collars, which made it easier for the rabbits to move. This alternative method not only facilitated the rabbits' movements but also reduced the stress associated with regular collars. It was noted that the animals adapted more easily to postoperative care when wearing socks.

In the present study, topical antibiotics were administered along with postoperative meloxicam. Based on the present findings, it was determined that spaying five rabbits with ketamine and xylazine at the indicated dosages was safe which supported by the study of xylazine and ketamine doses Yadav¹⁰.

4. Conclusion

There were no health risk factors associated with spaying rabbits under injectable general anaesthesia using ketamine 30 mg/kg and xylazine 5 mg/kg bw IM in a field context.

Declarations

Competing interests

The authors of the present study claimed no conflict of interest.

Acknowledgments

The authors expressed gratitude to the supportive staff members of the Sahidul Alam Quader Teaching Veterinary Hospital, Chattogram Veterinary and Animal Sciences University, Chattogram, Bangladesh for their valuable support.

Funding

There was no funding for the present study.

Authors' contributions

Saroj Kumar Yadav prepared the main manuscript and surgery, Mushfika Tabassum and Sunil Yadav prepared the manuscript edition and surgery, and Muhammad Ahaduzzaman supervised the manuscript editing. All authors have read and approved the final edition of the manuscript before publication in the journal.

Availability of data and materials

The data of the manuscript is available on request from the corresponding author.

Ethical considerations

Ethical issues, including plagiarism, consent to publish, misconduct, data fabrication and/or falsification, double publication and/or submission, and redundancy, have been checked by all the authors. The present study did not assist AI or AI tools in conducting and writing the manuscript.

References

- Kırşan İ, Enginler SÖ, Toydemir TSF, Erzenin ÖM, Sönmez K, and Şennazlı G. Gynaecological complications following improper ovariohysterectomy in a dog. *Int J Vet Sci.* 2013; 2(4): 121-124. Available at: <http://www.ijvets.com/pdf-files/Volume-2-no-4-2013/121-124.pdf>
- Quesenberry K, and Carpenter JW, editors. *Ferrets, rabbits and rodents. Clinical Medicine and surgery.* 3rd ed. Saunders. 2011. Available at: https://www.google.com/books/edition/_/VvICUGYAWtUC?hl=en&gbpv=0
- Perpiñán D. Rabbit neutering. *Companion Anim.* 2019; 24(4): 217-225. DOI: [10.12968/coan.2019.24.4.217](https://doi.org/10.12968/coan.2019.24.4.217)
- Freeman LJ, Ferguson N, Fellenstein C, Johnson R, and Constable PD. Evaluation of learning curves for ovariohysterectomy of dogs and cats and castration of dogs. *J Am Vet Med Assoc.* 2017; 251(3): 322-332. DOI: [10.2460/javma.251.3.322](https://doi.org/10.2460/javma.251.3.322)
- Pohl VH, Carregaro AB, Lopes C, Gehrcke MI, Muller DCM, and Garlet CD. Epidural anesthesia and postoperative analgesia with alpha-2 adrenergic agonists and lidocaine for ovariohysterectomy in bitches. *Can J Vet Res.* 2012; 76(3): 215-220. Available at: <https://www.ingentaconnect.com/content/cvma/cjvr/2012/00000076/00000003/art00009>
- Bennett RA, and Pye GF, editors. *Rabbit soft tissue surgery. Surgery of exotic animals.* John Wiley and Sons Inc., 2022. p. 240-276. Available at: https://books.google.com/books?hl=en&lr=&id=4tRHEAAQBAJ&oi=fnd&pg=PA240&ots=wkWEH13s7G&sig=cr66e5CLEtvc4xJvKE4Epv_Dlw#v=onepage&q&f=false
- Orr HE, Roughan JV, Flecknell PA. Assessment of ketamine and medetomidine anaesthesia in the domestic rabbit. *Vet Anaesth Analg.* 2005; 32(5): 271-279. DOI: [10.1111/j.1467-2995.2005.00211.x](https://doi.org/10.1111/j.1467-2995.2005.00211.x)
- Grint NJ, Murison PJ. A comparison of ketamine-midazolam and ketamine-medetomidine combinations for induction of anaesthesia in rabbits. *Vet Anaesth Analg.* 2008; 35(2): 113-121. DOI: [10.1111/j.1467-2995.2007.00362.x](https://doi.org/10.1111/j.1467-2995.2007.00362.x)
- Henke J, Astner S, Brill T, Eissner B, Busch R, and Erhardt W. Comparative study of three intramuscular anaesthetic combinations (medetomidine/ketamine, medetomidine/fentanyl/midazolam and xylazine/ketamine) in rabbits. *Vet Anaesth Analg.* 2005; 32(5): 261-270. DOI: [10.1111/j.1467-2995.2005.00242.x](https://doi.org/10.1111/j.1467-2995.2005.00242.x)
- Yadav SK. Anesthesia management for emergency cesarean section in a rabbits. *J Anesth Crit Care Open Access.* 2018; 10(5): 163-165. DOI: [10.15406/jaccoa.2018.10.00385](https://doi.org/10.15406/jaccoa.2018.10.00385)
- Murugesan V, Arunachalam K, Shanmugam K, and Palanivel M. Comparative study on midline and lateral flank approaches for ovariohysterectomy in cats. *Pharma Innov J.* 2020; 9(7): 191-193.
- Richardson C, and Flecknell P. Routine neutering of rabbits and rodents. In *Practice.* 2006; 28(2): 70-79. DOI: [10.1136/inpract.28.2.70](https://doi.org/10.1136/inpract.28.2.70)
- Varga M. General surgical principles and neutering. *Textbook of rabbit medicine.* 2nd ed. Elsevier, 2014. p. 429-434.
- Hanan MS, Riad EM, and el-Khouly NA. Antibacterial efficacy and pharmacokinetic studies of ciprofloxacin on *Pasteurella multocida* infected rabbits. *Dtsch Tierärztl Wochenschr.* 2000; 107(4): 151-155. Available at: <https://pubmed.ncbi.nlm.nih.gov/10829566/>
- Hossain I, Al-Arefin KS, Pranto RA, Sarker D, and Sobur KA. Ovariohysterectomy (Spaying) in a rabbit: A case report from Bangladesh. *Res J Vet Pract.* 2024; 12(4): 52-55. DOI: [10.17582/journal.rjvp/2024/12.4.52.55](https://doi.org/10.17582/journal.rjvp/2024/12.4.52.55)
- Carpenter JW, and Harms CA. *Rabbits.* In: Fisher P, and Graham JE, editors. *Carpenter's exotic animal formulary.* 6th ed. Saunders, 2022. p. 574-625. Available at: <https://www.sciencedirect.com/book/edited-volume/9780323833929/carpenters-exotic-animal-formulary>