



Systematic Review Article

Preoperative Imaging in Predicting Post-Surgical Complications in Small Animals: Insights from *In Vivo* Studies

Foroogh Alsadat Mousavi Fard¹, Hasan Ahmadzadeh Rishchri², Mohammad Alihosseini³, Arshia Neshat Taherzadeh⁴, and Ronak Roshangah^{5*}

¹ Department of Clinical Sciences, Faculty of Veterinary Medicine, Islamic Azad University, Shoushtar Branch, Khuzestan, Iran

² Department of Clinical Sciences, Faculty of Veterinary Medicine, Shiraz University, Shiraz, Iran

³ Department of Clinical Sciences, Faculty of Veterinary Medicine, Islamic Azad University, Baft Branch, Kerman, Iran

⁴ Department of Clinical Sciences, Faculty of Veterinary Medicine, Islamic Azad University, Science and Research Branch, Tehran, Iran

⁵ Department of Clinical Sciences, Faculty of Veterinary Medicine, Sanandaj Branch, Islamic Azad University, Sanandaj, Kurdistan Province, Iran

* Corresponding author: Ronak Roshangah, Department of Clinical Sciences, Faculty of Veterinary Medicine, Sanandaj Branch, Islamic Azad University, Sanandaj, Kurdistan Province, Iran. Email: ro.roshangah@gmail.com

ARTICLE INFO

Article History:

Received: 15/04/2026

Received: 17/05/2026

Accepted: 05/06/2026

Publish: 29/06/2026



Keywords:

In vivo

Post-surgical complication

Predictive value

Preoperative imaging

Small animal surgery

ABSTRACT

Preoperative imaging is a key tool in small-animal surgery; however, its predictive value for postoperative complications remains to be carefully investigated. The present study aimed to assess the predictive value and limitations of preoperative radiology for postoperative complications in small animals, based on evidence from *in vivo* studies. A systematic search of PubMed, Scopus, Web of Science, and Google Scholar databases was performed between 2020 and 2025 using keywords related to preoperative imaging, postoperative complications, dogs, cats, and animal models. Inclusion criteria included *in vivo* experimental studies on small animals (dogs and cats), reporting at least one preoperative imaging modality, including radiography, ultrasound, computed tomography (CT), and magnetic resonance imaging (MRI). Case reports, case series with a sample size of less than 5, and review articles were excluded. Out of 522 initial studies, duplicates were removed, and titles and abstracts were screened. This process resulted in 135 articles being fully evaluated, from which 116 studies were excluded, leaving 19 studies for inclusion. The positive predictive value of imaging for complications such as intestinal anastomotic leakage, pneumothorax after thoracotomy, and uroemia after urinary tract surgery was moderate to acceptable. However, major limitations were present, including low sensitivity for detecting mild adhesions, inability to predict individual fibrotic responses, and failure to detect local microbiota. Additionally, normal preoperative radiological findings in small animals were associated with significant postoperative complications. Preoperative radiology in small animals has moderate to high predictive value for specific complications such as syringomyelia. However, owing to its limited sensitivity in detecting microscopic involvement and variations in individual tissue responses, preoperative radiology cannot serve as the only tool for clinical decision-making. Combining imaging with serum biomarkers and complementary laparoscopic evaluation are necessary for predicting post-surgical complications in small animals.

1. Introduction

Surgery in small animals, especially in dogs and cats, has made significant progress in the last two decades, and complex procedures such as oncological, orthopedic, neurological, and gastrointestinal surgeries are increasingly performed in clinics¹⁻³. The success of a surgical procedure is not limited to the skill of the surgeon and the technique

used; the postoperative outcomes, particularly the occurrence of complications such as anastomotic leakage, sepsis, intra-abdominal adhesions, pneumothorax, aspiration pneumonia, and urinary tract uremia, are the main factors of treatment success⁴⁻⁶. Postoperative complications not only increase the length of

Cite this paper as: Mousavi Fard FA, Ahmadzadeh Rishchri H, Alihosseini M, Neshat Taherzadeh A, and Roshangah R. Preoperative Imaging in Predicting Post-Surgical Complications in Small Animals: Insights from *In Vivo* Studies. 2026; 5(3): 52-58. DOI: 10.58803/jlar.v5i3.107



The Author(s). Published by Rovedar. This is an open-access article distributed under the terms of the Creative Commons Attribution License (<http://creativecommons.org/licenses/by/4.0>), which permits unrestricted use, distribution, and reproduction in any medium, provided the original work is properly cited.

hospitalization, mortality, and treatment costs, but also directly affect the animal's quality of life and owner satisfaction⁷⁻⁹. Therefore, the ability to predict these complications before surgery has always been a primary goal in veterinary medicine.

Preoperative imaging is widely used as a noninvasive and accessible tool to assess anatomy, identify underlying abnormalities, investigate adjacent organ involvement, and estimate the extent of the lesion before surgical incision^{10,11}. Common preoperative imaging methods include plain radiography, computed tomography (CT), and, in special cases, magnetic resonance imaging (MRI)^{12,13}. Each imaging method has a different ability to reveal anatomical and pathological details. For instance, in thoracotomy surgery, chest radiography may reveal a mild pneumothorax or effusion, while in abdominal surgery, ultrasound may demonstrate bowel wall thickening, mesenteric vasodilation, and signs of local inflammation^{14,15}. Moreover, CT has notable advantages, including high tissue resolution and the possibility of three-dimensional (3D) reconstruction, especially for assessing vascular and bony involvement¹⁶. Despite the widespread use of preoperative imaging in routine clinical practice, a major knowledge gap remains. Many veterinary surgeons have numerous clinical experiences in which preoperative imaging was completely normal, but the animal developed severe and sometimes fatal complications after surgery. This was a false-positive case in which imaging failed to detect an actual problem^{17,18}. On the other hand, X-rays sometimes revealed concerning signs, such as a mildly enlarged intestinal loop, prompting the veterinarian to expect a complication, but the subsequent surgery proceeded without any complications. This phenomenon is referred to as a false negative due to overprediction type¹⁹. The disparities between imaging predictions and actual surgical outcomes suggested that the current scientific evidence supporting or rejecting the use of imaging as a reliable predictive instrument for surgical procedures remained poorly understood²⁰.

Preoperative radiology can demonstrate gross structures but cannot predict the biological response of tissues to the presence of a foreign body (suture thread), local ischemia, or unknown infection²¹. In addition, there are numerous confounding factors, such as surgeon experience, surgical technique, suture quality, nutritional status, and the animal's immunity, as well as concomitant medications such as corticosteroids, none of which can be measured by imaging, but all are ultimately determinant factors in the occurrence of complications²². Most of the studies on the predictive value of preoperative imaging were *ex vivo* or human studies that were not directly applicable to small-animal veterinary practice^{17,19}. *In vivo* studies in dogs and cats that have specifically addressed the predictive value of preoperative imaging are few, sporadic, and often have small sample sizes or short follow-up periods^{2,23}. Existing studies have primarily concentrated on a particular imaging modality, such as CT, and a specific complication, namely intestinal anastomotic

leak. A comprehensive overview of the predictive value of different modalities across different surgical procedures remains to be established lacking²⁴. The present study aimed to assess the application and limitations of preoperative radiology in predicting postoperative complications in small animals based on evidence from *in vivo* studies.

2. Search criteria

The present systematic review adhered to the methodological standards outlined in the Preferred Reporting Items for Systematic Reviews and Meta-Analyses (PRISMA) statement²⁵. A comprehensive literature search was conducted in PubMed (MEDLINE), Scopus, Web of Science (Core Collection), and Google Scholar, targeting publications published between January 2020 and December 2025. The search strategy was designed using a combination of medical subject headings and keywords for PubMed and free-text keywords for other databases. The main keywords included preoperative imaging or preoperative radiology, preoperative radiography, preoperative ultrasound, preoperative CT, preoperative MRI, and post-surgical complications or postoperative complications, anastomotic leak, sepsis, pneumothorax, adhesion, urinary leakage, and small animals or dogs, canine, cats, feline, and *in vivo* NOT *ex vivo*, or cadaver. In addition, the reference lists of retrieved articles, as well as articles citing key studies, were checked using the cited-by feature in Google Scholar to minimize the risk of missing relevant studies (Figure 1). The inclusion criteria were precisely and pre-determined to encompass original experimental studies with an *in vivo* design involving small live animals of the species dog (*Canis familiaris*) or cat (*Felis catus*). Additionally, book chapters and retrospective studies that presented pertinent data on preoperative imaging and postoperative outcomes, including plain radiography, ultrasound, CT, or MRI performed prior to surgery, were included. The criteria required systematic and transparent recording of postoperative complications during follow-up, with a focus on late issues such as adhesions or chronic abscesses. Furthermore, only studies published in English or accompanied by an official English translation were considered. Exclusion criteria were included *ex vivo* or cadaveric studies, case reports and case series with a sample size of less than five, review and opinion articles, letters to the editor, conference abstracts without full text, and studies in which postoperative or intraoperative imaging was performed without recording preoperative imaging. The screening process was performed by two independent authors, who first reviewed the titles and abstracts, then potentially relevant articles were retrieved and evaluated in full text. The quality assessment of eligible studies was carried out independently by two authors. The preliminary search yielded 522 citations, which were reduced to 240 after eliminating duplicate records. Following title and abstract screening, a total of 135 publications were considered suitable for full-text examination. Then, 116 articles were excluded for different reasons, including lack of follow-up,

sample size, lack of specific preoperative imaging, and *ex vivo* design. Ultimately, 19 studies of acceptable quality

were deemed eligible for inclusion in the present study.

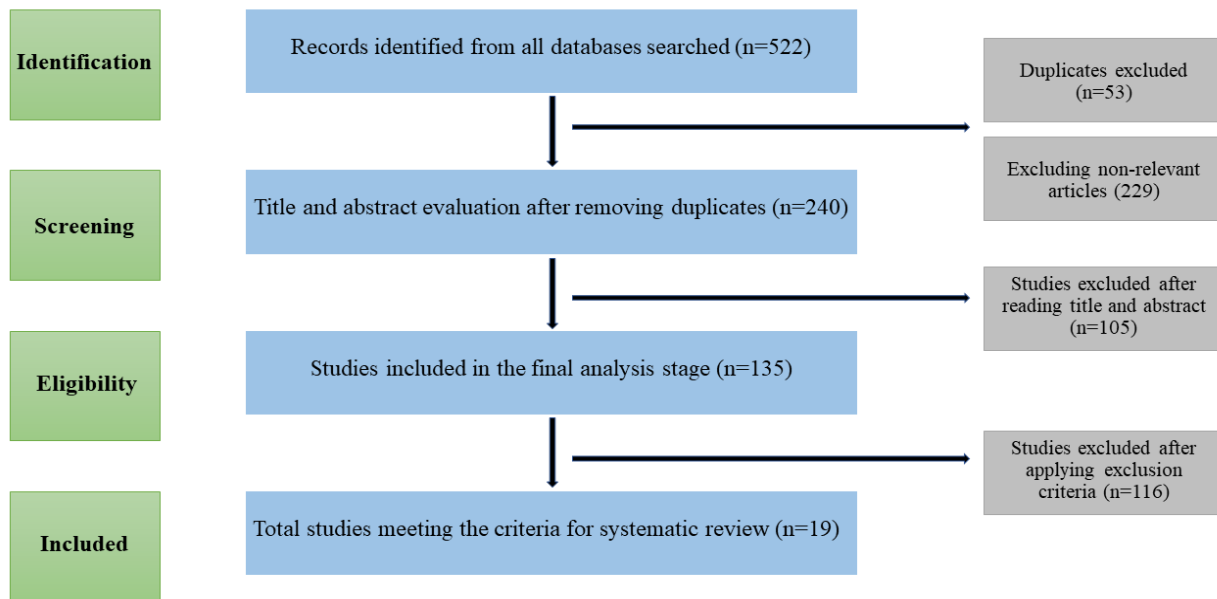


Figure 1. The PRISMA flow diagram for study design and literature selection procedure

3. Results

Among the eligible studies, there were considerable differences in the type of preoperative imaging modality and the type of postoperative complication studied^{26,27}. Some studies focused on plain chest or abdominal radiography, while another group of studies used ultrasound as the primary prognostic tool^{28,29}. Fewer studies used CT and, in rare cases, MRI^{26,28}. The complications associated with the predictive value of preoperative imaging ranged from anastomotic leaks in gastrointestinal surgery, pneumothorax following thoracotomy, intra-abdominal adhesions, urinary tract urolithiasis, and surgical site infections^{30,31}. The studies had different designs, making direct comparisons challenging, but these differences highlighted shared patterns in their predictive values. Several studies indicated that when preoperative imaging revealed a clear and measurable structural abnormality, such as abnormal bowel wall thickness, air or fluid in anomalous cavities, or significant bony involvement in small animals, its positive predictive value was relatively acceptable, typically ranging from 6% to 80% in veterinary studies^{11,32,33}. When a radiological finding was clearly visible and matched the expected pathophysiology of the condition, the chance of that same complication occurring after surgery was higher^{34,35}. For instance, in intestinal anastomosis, the presence of free fluid with air bubbles on preoperative ultrasound, which is a sign of transmural inflammation, was often associated with anastomotic leakage in the postoperative period^{36,37}. Also, in thoracotomy, preoperative radiographs showing significant pleural effusion were associated³⁸⁻⁴⁰ with prolonged pneumothorax and the need for repeated drainage⁴¹⁻⁴³. However, it is important to emphasize that even in ideal circumstances, imaging has never been a definitive predictor, and numerous cases of false positives (abnormal findings but

no clinical complication) have been reported⁴⁴⁻⁴⁷.

A major challenge of preoperative imaging in small animals was its low negative predictive value⁴⁸. Therefore, the absence of pathological findings on radiology (completely normal imaging) can never reliably guarantee the absence of a complication after surgery⁴⁹. In many cases, small animals with normal preoperative imaging developed serious, sometimes life-threatening complications after surgery^{41,43,50}. Normal imaging shadowing occurs primarily because imaging techniques cannot detect microscopic processes such as immature adhesions, mild inflammation without wall thickening, subclinical ischemia, or local bacterial contamination^{51,52}. When comparing different imaging techniques, a relatively clear pattern emerged; CT and MRI, which have higher resolution, were more effective at predicting outcomes than standard X-rays. However, even CT and MRI could not fully address the primary issues, as these imaging methods were unable to predict the biological response of tissues during or after surgery^{53,54}. In addition, in all 19 studies, several confounding factors were identified that affected the predictive power of imaging. Factors influencing outcomes included the surgeon's skill and technique, with less experienced surgeons experiencing more complications even when X-ray results were the same. Additionally, the animal's overall health, including albumin levels and immune system function, played a role. The use of anti-inflammatory medications or steroids, which can affect scar tissue formation, and other pre-existing conditions, such as chronic kidney failure, also contributed to diabetes^{55,42}.

4. Discussion

A critical challenge identified in the studies was the inherent inability of preoperative imaging techniques to detect pathological processes at the microscopic or

submillimeter level scale⁴⁷. More specifically, preoperative X-rays can distinctly reveal a substantial tumor, a notably swollen intestinal loop, or a substantial accumulation of air within the thoracic cavity. However, these findings were largely ineffective at identifying early scar tissue (immature adhesions), mild surface inflammation that has not yet caused thickening of the intestinal wall, or small regions of bacterial proliferation on the external surface of the intestines⁵⁶. In several studies, preoperative imaging was reported to be completely normal; however, after opening the abdominal cavities of small animals, surgeons encountered extensive but thin, transparent adhesions that were not detectable by either ultrasound or CT^{57,58}. Adhesions not only interrupted the surgical procedure but also directly raised the risk of injuring nearby organs and extended the surgery duration⁵⁹. Therefore, one of the main challenges was that imaging cannot replace direct surgical exploration to assess adhesions and mild inflammation^{57,60}. Another major challenge was clinical false positives preoperative radiological findings, which exhibited highly abnormal and alarming conditions, preparing the surgeon for a complex postoperative complication. However, in practice, the surgery was performed without particular challenge, and the animal's recovery period proceeded without major complications^{2,61}. In many of these false positive cases, the radiological finding represented a chronic and persistent inflammatory process that no longer posed a risk of causing acute postoperative issues, or it was a degenerative, non-progressive anatomical change that did not interfere with tissue repair and wound healing. The challenge was intensified when the surgeon decided to change the surgical site, widen the incision, incorporate a more invasive procedure, or even cancel the surgery based

on these false-positive findings⁶². Another challenge was the insufficient consideration of clinical confounders when interpreting radiological data. Preoperative imaging provides a static view of anatomy and pathology at a specific time point, typically a few days to a few weeks prior to surgery. However, preoperative imaging does not consider clinical factors such as the animal's nutritional status (especially low albumin levels), immune function, use of immunosuppressive medicines, renal or hepatic failure, or the unique fibrotic response in each case⁶³. Two animals with identical radiological findings can follow completely different postoperative conditions. This difference might be due to genetic and epigenetic factors that influence the rate and quality of tissue repair, which cannot be measured by any imaging technique⁶⁴.

Preoperative imaging alone can never serve as a definitive and independent predictor of postoperative complications in small animals^{65,66}. Imaging techniques are no longer regarded as the sole predictor but rather as one of the inputs to a clinical decision support system. A multivariate approach has the potential to substantially diminish false positives and to identify high-risk cases even when imaging results appear normal. The most promising future development in this field is the integration of artificial intelligence and deep learning with radiomics to identify hidden features in preoperative imaging data that are invisible to the human eye⁶⁷. Radiomics is the process of quantitatively extracting hundreds of features, including texture features, spatial patterns, and signal heterogeneity, from radiological images, which can be related to subcellular biological processes such as angiogenesis, fibrosis, and inflammation⁶⁸. Figure 2 illustrated a radiomics model process.

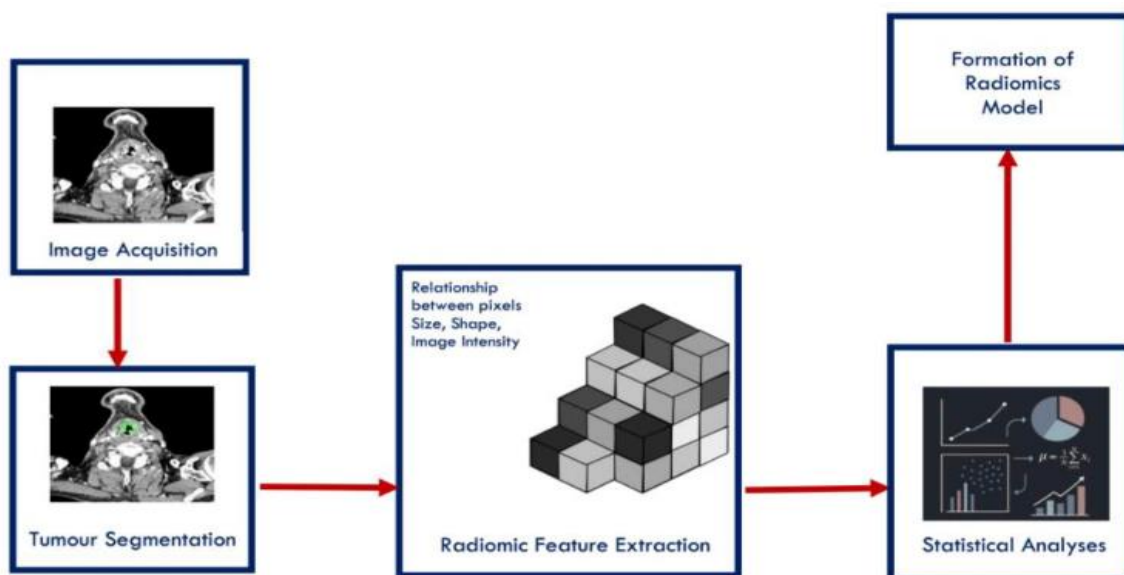


Figure 2. Formation of a radiomics model workflow diagram. The diagram shows the process of building a radiomics model in five steps: First, using medical images (such as CT or MRI), the tumor region was segmented on the images. Next, the relationships between pixels in terms of size, shape, and brightness were examined, and radiomics features were extracted. Finally, using these features, a predictive model was formed that can be used in diagnosis, prognosis, or assessment of response to treatment (Source: MDPI Copyright, 2026; Rajgor et al.⁶⁹)

Deep learning-based methods, with particular emphasis on convolutional neural networks (CNNs), can analyze raw

images to identify high-dimensional features associated with postoperative adverse conditions, all without manual input from humans^{70,71}. In the future, an advanced system could analyze a CT or ultrasound image of an animal and quickly generate a detailed map showing adhesion likelihood, the risk of anastomotic leaks, and an estimate of tissue healing time, all with greater accuracy than experienced human radiologists^{72,73}. Overall, the future of

predicting postoperative complications in small animals can be improved by advances in imaging technology and by the intelligent integration of imaging, molecular biomarkers, and artificial intelligence into a comprehensive clinical decision-support system. Veterinary surgeons are advised to view radiological findings as a guide rather than a definitive predictor, and to always exercise clinical caution alongside imaging (Figure 3).

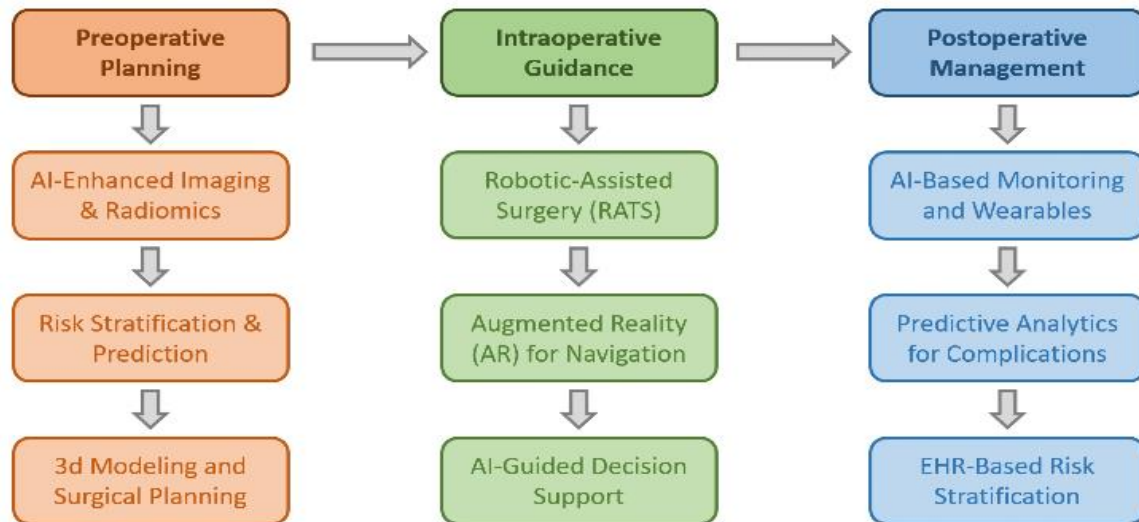


Figure 3. The role of artificial intelligence across different phases of thoracic surgery. In the preoperative phase, AI enhances imaging through radiomics, assists in risk stratification, and supports 3D modeling for surgical planning (Source: MDPI Copyright, 2025; Leivaditis et al.⁷⁴)

5. Conclusion

The current study indicated that preoperative imaging, including radiography, ultrasound, CT, and MRI, although valuable for identifying obvious organ abnormalities and the surgical procedure, cannot alone serve as a definitive, independent predictive tool for postoperative complications. The current findings highlighted that animal and *in vivo* studies are essential for understanding how biological variability, individual physiology, and unpredictable surgical factors can cause imaging results to misalign with clinical outcomes. Future studies should focus on developing multivariate predictive models, conducting prospective studies with a uniform protocol, and utilizing artificial intelligence and radiomics to extract latent features from images. Although radiographic evaluation provides valuable diagnostic information, it should be interpreted with caution.

Declarations

Authors' contributions

Foroogh Alsadat Mousavi Fard, Hasan Ahmadzadeh Rishchri, and Mohammad Alihosseini drafted the manuscript. Arshia Neshat Taherzadeh and Ronak Roshangah designed the method, wrote the findings and discussion sections,

References

1. Ellison GW, Case JB, and Regier PJ. Intestinal surgery in small animals: Historical foundations, current thinking, and future horizons. *Vet Surg*. 2019; 48(7): 1171-1180. DOI: [10.1111/vsu.13275](https://doi.org/10.1111/vsu.13275)
2. Follette CM, Giuffrida MA, Balsa IM, Culp WT, Mayhew PD, Oblak ML, et

revised the manuscript draft, and checked for grammatical errors. All authors checked and approved the final edition of the manuscript for publication in the present journal.

Availability of data and materials

This review article is based entirely on previously published studies. All data supporting the findings of this review are available within the article and are available upon request from the corresponding author.

Competing interests

The authors declared that they have no competing interests.

Ethical considerations

All the authors confirmed that ethical concerns, such as plagiarism, permission to publish, research misconduct, data fabrication or falsification, duplicate submissions, and redundant publication, have been thoroughly reviewed. No AI-assisted technologies were used in the generation of this manuscript.

Funding

No external funding was received for the present study.

- al. A systematic review of criteria used to report complications in soft tissue and oncologic surgical clinical research studies in dogs and cats. *Vet Surg*. 2020; 49(1): 61-69. DOI: [10.1111/vsu.13279](https://doi.org/10.1111/vsu.13279)
3. Bojrab MJ, Waldron DR, and Toombs JP. Current techniques in small animal surgery, 5th ed. CRC Press; 2014. DOI: [10.1201/b17702](https://doi.org/10.1201/b17702)
4. Nelson LL. Surgical site infections in small animal surgery. *Vet Clin*

- North Am Small Anim. Pract. 2011; 41(5): 1041-1056. DOI: [10.1016/j.cvsm.2011.05.010](https://doi.org/10.1016/j.cvsm.2011.05.010)
5. Griffon D, and Hamaide A. Complications in small animal surgery. John Wiley & Sons, 2016. p. 8-14. DOI: [10.1002/9781119421344](https://doi.org/10.1002/9781119421344)
 6. Verwilghen D, and Singh A. Fighting surgical site infections in small animals: Are we getting anywhere?. *Vet Clin North Am Small Anim Pract.* 2015; 45(2): 243-276. DOI: [10.1016/j.cvsm.2014.11.001](https://doi.org/10.1016/j.cvsm.2014.11.001)
 7. Pailler S, Dolan ED, Slater MR, Gayle JM, Lesnikowski SM, DeClementi C, et al. Owner-reported long-term outcomes, quality of life, and longevity after hospital discharge following surgical treatment of pyometra in bitches and queens. *J Am Vet Med Assoc.* 2022; 260(2): 57-63. DOI: [10.2460/javma.20.12.0714](https://doi.org/10.2460/javma.20.12.0714)
 8. Greenhalgh SN, Reeve JA, Johnstone T, Goodfellow MR, Dunning MD, O'Neill EJ, et al. Long-term survival and quality of life in dogs with clinical signs associated with a congenital portosystemic shunt after surgical or medical treatment. *J Am Vet Med Assoc.* 2014; 245(5): 527-533. DOI: [10.2460/javma.245.5.527](https://doi.org/10.2460/javma.245.5.527)
 9. Kipperman BS, Kass PH, and Rishniw M. Factors that influence small animal veterinarians' opinions and actions regarding cost of care and effects of economic limitations on patient care and outcome and professional career satisfaction and burnout. *J Am Vet Med Assoc.* 2017; 250(7): 785-794. DOI: [10.2460/javma.250.7.785](https://doi.org/10.2460/javma.250.7.785)
 10. Moran CM, and Thomson AJ. Preclinical ultrasound imaging-a review of techniques and imaging applications. *Front Phys.* 2020; 8: 124. DOI: [10.3389/fphy.2020.00124](https://doi.org/10.3389/fphy.2020.00124)
 11. Kagadis GC, Loudos G, Katsanos K, Langer SG, and Nikiforidis GC. *In vivo* small animal imaging: Current status and future prospects. *Med Phys.* 2010; 37(12): 6421-6442. DOI: [10.1118/1.3515456](https://doi.org/10.1118/1.3515456)
 12. Yitbarek D, and Dagnaw GG. Application of advanced imaging modalities in veterinary medicine: A review. *Vet Med Res Rep.* 2022; 13: 117-130. DOI: [10.2147/VMRR.S367040](https://doi.org/10.2147/VMRR.S367040)
 13. Gielen I, Caelenberg A, and Bree H. Clinical applications of computed tomography (CT) and magnetic resonance imaging (MRI) in small animals. *Eur J Companion Anim Pract.* 2012; 22(4): 84-103. Available at: <http://hdl.handle.net/1854/LU-3091268>
 14. Ufuk F, Ocak I, Chelala L, and Landeras L. Postoperative pulmonary complications: Clinical and imaging insights. *Balkan Med J.* 2025; 42(5): 405. DOI: [10.4274/balkanmedj.galenos.2025.2025-7.135](https://doi.org/10.4274/balkanmedj.galenos.2025.2025-7.135)
 15. Safai Zadeh E, Görg C, Prosch H, Horn R, Janssen C, and Dietrich CF. The role of thoracic ultrasound for diagnosis of diseases of the chest wall, the mediastinum, and the diaphragm-narrative review and pictorial essay. *Diagnostics.* 2023; 13(4): 767. DOI: [10.3390/diagnostics13040767](https://doi.org/10.3390/diagnostics13040767)
 16. Vervoorn MT, Wulfse M, Mohamed Hoesein FA, Stellingwerf M, van der Kaaij NP, and de Heer LM. Application of three-dimensional computed tomography imaging and reconstructive techniques in lung surgery: A mini-review. *Front Surg.* 2022; 9: 1079857. DOI: [10.3389/fsurg.2022.1079857](https://doi.org/10.3389/fsurg.2022.1079857)
 17. Johnston SA, and Tobias KM. *Veterinary surgery: Small animal.* 2nd ed. Elsevier, 2017.
 18. Mayhew PD. Complications of minimally invasive surgery in companion animals. *Vet Clin North Am Small Anim Pract.* 2011; 41(5): 1007-1021. DOI: [10.1016/j.cvsm.2011.05.008](https://doi.org/10.1016/j.cvsm.2011.05.008)
 19. Stieger-Vanegas SM. *Gastrointestinal imaging. Clinical small animal internal medicine.* Wiley, 2020. p. 467-505. DOI: [10.1002/9781119501237.ch48](https://doi.org/10.1002/9781119501237.ch48)
 20. Kneissl SM, Prüllage ML, Vali Y, Vodnarek J, Klang A, Dolezal M, et al. Comparison of pre- and intraoperative findings in 35 cats and 60 dogs presenting with gastrointestinal signs. *Front Vet Sci.* 2025; 12: 1562792. DOI: [10.3389/fvets.2025.1562792](https://doi.org/10.3389/fvets.2025.1562792)
 21. Boston S, and Henderson RA. Role of surgery in multimodal cancer therapy for small animals. *Vet Clin North Am Small Anim Pract.* 2014; 44(5): 855-870. DOI: [10.1016/j.cvsm.2014.05.008](https://doi.org/10.1016/j.cvsm.2014.05.008)
 22. Frey TN, Hoelzler MG, Scavelli TD, Fulcher RP, and Bastian RP. Risk factors for surgical site infection-inflammation in dogs undergoing surgery for rupture of the cranial cruciate ligament: 902 cases (2005-2006). *J Am Vet Med Assoc.* 2010; 236(1): 88-94. DOI: [10.2460/javma.236.1.88](https://doi.org/10.2460/javma.236.1.88)
 23. Blondel M, Sonet J, Cachon T, Ségard-Weisse E, Ferrand FX, and Carozzo C. Comparison of imaging techniques to detect migrating foreign bodies. Relevance of preoperative and intraoperative ultrasonography for diagnosis and surgical removal. *Vet Surg.* 2021; 50(4): 833-842. DOI: [10.1111/vsu.13607](https://doi.org/10.1111/vsu.13607)
 24. Guiot LP, and Déjardin LM. Perioperative imaging in minimally invasive osteosynthesis in small animals. *Vet Clin North Am Small Anim Pract.* 2012; 42(5): 897-911. DOI: [10.1016/j.cvsm.2012.06.003](https://doi.org/10.1016/j.cvsm.2012.06.003)
 25. Moher D, Liberati A, Tetzlaff J, Altman DG, and Group P. Preferred reporting items for systematic reviews and meta-analyses: The PRISMA statement. *Int J Surg.* 2010; 8(5): 336-341. DOI: [10.1016/j.ijsu.2010.02.007](https://doi.org/10.1016/j.ijsu.2010.02.007)
 26. Alam IS, Steinberg I, Vermesh O, van den Berg NS, Rosenthal EL, van Dam GM, et al. Emerging intraoperative imaging modalities to improve surgical precision. *Mol Imaging Biol.* 2018; 20(5): 705-715. DOI: [10.1007/s11307-018-1227-6](https://doi.org/10.1007/s11307-018-1227-6)
 27. Knight SR, Shaw CA, Pius R, Drake TM, Norman L, Ademuyiwa AO, et al. Global variation in postoperative mortality and complications after cancer surgery: A multicentre, prospective cohort study in 82 countries. *Lancet.* 2021; 397(10272): 387-397. DOI: [10.1016/S0140-6736\(21\)00001-5](https://doi.org/10.1016/S0140-6736(21)00001-5)
 28. Gans SL, Stoker J, and Boermeester MA. Plain abdominal radiography in acute abdominal pain; past, present, and future. *Int J Gen Med.* 2012; 5: 525-533. DOI: [10.2147/IJGM.S17410](https://doi.org/10.2147/IJGM.S17410)
 29. von Stade L, and Sadar MJ. Advanced imaging of small mammals. *Adv Small Anim Care.* 2024; 5(1): 51-65. DOI: [10.1016/j.yasa.2024.06.004](https://doi.org/10.1016/j.yasa.2024.06.004)
 30. Hölscher AH, Vallböhrer D, and Brabender J. The prevention and management of perioperative complications. *Best Pract Res Clin Gastroenterol.* 2006; 20(5): 907-923. DOI: [10.1016/j.bpg.2006.05.002](https://doi.org/10.1016/j.bpg.2006.05.002)
 31. Tweedle E. Postoperative complications. In: Watson C, and Davies J, editors. *Ellis and Calne's Lecture notes in general surgery.* Wiley, 2023. p. 27-48. DOI: [10.1002/97811394322008.ch5](https://doi.org/10.1002/97811394322008.ch5)
 32. Cunha L, Horvath I, Ferreira S, Lemos J, Costa P, Vieira D, et al. Preclinical imaging: An essential ally in modern biosciences. *Mol Diagn Ther.* 2014; 18(2): 153-173. DOI: [10.1007/s40291-013-0062-3](https://doi.org/10.1007/s40291-013-0062-3)
 33. Hurtig MB, Buschmann MD, Fortier LA, Hoemann CD, Hunziker EB, Jurvelin JS, et al. Preclinical studies for cartilage repair: Recommendations from the international cartilage repair society. *Cartilage.* 2011; 2(2): 137-152. DOI: [10.1177/1947603511401905](https://doi.org/10.1177/1947603511401905)
 34. Hildebrandt IJ, Su H, and Weber WA. Anesthesia and other considerations for *in vivo* imaging of small animals. *ILAR J.* 2008; 49(1): 17-26. DOI: [10.1093/ilar.49.1.17](https://doi.org/10.1093/ilar.49.1.17)
 35. Van der Linden A, Van Camp N, Ramos-Cabrer P, and Hoehn M. Current status of functional MRI on small animals: Application to physiology, pathophysiology, and cognition. *NMR Biomed.* 2007; 20(5): 522-545. DOI: [10.1002/nbm.1131](https://doi.org/10.1002/nbm.1131)
 36. Albahrawy M, Abass M, Mosbah E, Karrouf G, and Zaghoul A. A narrative review on pathophysiology and the trends in preventing colon anastomotic leakage in animals. *Mansoura Vet Med J.* 2024; 25(2): 3. DOI: [10.35943/2682-2512.1235](https://doi.org/10.35943/2682-2512.1235)
 37. Guyton KL, Hyman NH, and Alverdy JC. Prevention of perioperative anastomotic healing complications: Anastomotic stricture and anastomotic leak. *Adv Surg.* 2016; 50(1): 129. DOI: [10.1016/j.yasu.2016.03.011](https://doi.org/10.1016/j.yasu.2016.03.011)
 38. Johnson C, Lapsley J, Piegols H, and Selmic L. Surgical approach and presence of preoperative pleural effusion impact thoracostomy tube usage in dogs and cats following thoracic surgery for suspected neoplasia. *J Am Vet Med Assoc.* 2024; 262(7): 1-7. DOI: [10.2460/javma.24.01.0005](https://doi.org/10.2460/javma.24.01.0005)
 39. Pawloski DR, and Broadus KD. Pneumothorax: A review. *J Am Anim Hosp Assoc.* 2010; 46(6): 385-397. DOI: [10.5326/0460385](https://doi.org/10.5326/0460385)
 40. Epstein SE. Exudative pleural diseases in small animals. *Vet Clin North Am Small Anim Pract.* 2014; 44(1): 161-180. DOI: [10.1016/j.cvsm.2013.08.005](https://doi.org/10.1016/j.cvsm.2013.08.005)
 41. Lynch KC, Oliveira CR, Matheson JS, Mitchell MA, and O'Brien RT. Detection of pneumothorax and pleural effusion with horizontal beam radiography. *Vet Radiol Ultrasound.* 2012; 53(1): 38-43. DOI: [10.1111/j.1740-8261.2011.01854.x](https://doi.org/10.1111/j.1740-8261.2011.01854.x)
 42. Dickson R, Scharf VF, Michael AE, Walker M, Thomson C, Grimes J, et al. Surgical management and outcome of dogs with primary spontaneous pneumothorax: 110 cases (2009-2019). *J Am Vet Med Assoc.* 2021; 258(11): 1229-1235. DOI: [10.2460/javma.258.11.1229](https://doi.org/10.2460/javma.258.11.1229)
 43. Sériot P, Dunié-Mérigot A, Tréhiou CB, Blond L, Bernardin F, Poujol L, et al. Treatment and outcome of spontaneous pneumothorax secondary to suspected migrating vegetal foreign body in 37 dogs. *Vet Rec.* 2021; 189(4): 22-41. DOI: [10.1002/vetr.22](https://doi.org/10.1002/vetr.22)
 44. Lamb CR. Veterinary diagnostic imaging: Probability, accuracy and impact. *Vet J.* 2016; 215: 55-63. DOI: [10.1016/j.tvjl.2016.03.017](https://doi.org/10.1016/j.tvjl.2016.03.017)
 45. Lamb CR, and David FH. Advanced imaging: Use and misuse. *J Feline Med Surg.* 2012; 14(7): 483-497. DOI: [10.1177/1098612X12451550](https://doi.org/10.1177/1098612X12451550)

46. Chang JM, Lee HJ, Goo JM, Lee H-Y, Lee JJ, Chung J-K, et al. False positive and false negative FDG-PET scans in various thoracic diseases. *Korean J Radiol.* 2006; 7(1): 57-69. DOI: [10.3348/kjr.2006.7.1.57](https://doi.org/10.3348/kjr.2006.7.1.57)
47. Lauber DT, Fülöp A, Kovács T, Szigeti K, Máthé D, and Szijártó A. State of the art *in vivo* imaging techniques for laboratory animals. *Lab Anim.* 2017; 51(5): 465-478. DOI: [10.1177/0023677217695852](https://doi.org/10.1177/0023677217695852)
48. Balaban RS, and Hampshire VA. Challenges in small animal noninvasive imaging. *ILAR J.* 2001; 42(3): 248-262. DOI: [10.1093/ilar.42.3.248](https://doi.org/10.1093/ilar.42.3.248)
49. Gabrielson K, Maronpot R, Monette S, Mlynarczyk C, Ramot Y, Nyska A, et al. *In vivo* imaging with confirmation by histopathology for increased rigor and reproducibility in translational research: A review of examples, options, and resources. *ILAR J.* 2018; 59(1): 80-98. DOI: [10.1093/ilar/ily010](https://doi.org/10.1093/ilar/ily010)
50. de Brito Galvao JF, and Chew DJ. Metabolic complications of endocrine surgery in companion animals. *Vet Clin North Am Small Anim Pract.* 2011; 41(5): 847-868. DOI: [10.1016/j.cvsm.2011.05.012](https://doi.org/10.1016/j.cvsm.2011.05.012)
51. Jones MA, MacCuaig WM, Frickenstein AN, Camalan S, Gurcan MN, Holter-Chakrabarty J, et al. Molecular imaging of inflammatory disease. *Biomedicines.* 2021; 9(2): 152. DOI: [10.3390/biomedicines9020152](https://doi.org/10.3390/biomedicines9020152)
52. Peñate Medina T, Kolb JP, Hüttmann G, Huber R, Peñate Medina O, Ha L, et al. Imaging inflammation-from whole body imaging to cellular resolution. *Front Immunol.* 2021; 12: 692222. DOI: [10.3389/fimmu.2021.692222](https://doi.org/10.3389/fimmu.2021.692222)
53. Koo V, Hamilton P, and Williamson K. Non-invasive *in vivo* imaging in small animal research. *Anal Cell Pathol.* 2006; 28(4): 127-139. DOI: [10.1155/2006/245619](https://doi.org/10.1155/2006/245619)
54. Bartling SH, Stiller W, Semmler W, and Kiessling F. Small animal computed tomography imaging. *Curr Med Imaging.* 2007; 3(1): 45-59. DOI: [10.2174/157340507779940327](https://doi.org/10.2174/157340507779940327)
55. Li H, Zhang H, Tang Z, and Hu G. Micro-computed tomography for small animal imaging: Technological details. *Prog Nat Sci.* 2008; 18(5): 513-521. DOI: [10.1016/j.pnsc.2008.01.002](https://doi.org/10.1016/j.pnsc.2008.01.002)
56. Morrison ID, McLaughlin P, and Maher MM. Current status of imaging of the gastrointestinal tract: Imaging techniques and radiation issues. In: Adam A, Dixon AK, Gillard JH, editors. *Grainger & Allison's diagnostic radiology: Abdominal imaging.* 6th ed. Elsevier, 2015. p. 1-20.
57. Gerner-Rasmussen J, Donatsky AM, and Bjerrum F. The role of non-invasive imaging techniques in detecting intra-abdominal adhesions: A systematic review. *Langenbecks Arch Surg.* 2019; 404(6): 653-661. DOI: [10.1007/s00423-018-1732-8](https://doi.org/10.1007/s00423-018-1732-8)
58. Abdellatif A, Kramer M, Failing K, and Von Pückler K. Correlation between preoperative ultrasonographic findings and clinical, intraoperative, cytopathological, and histopathological diagnosis of acute abdomen syndrome in 50 dogs and cats. *Vet Sci.* 2017; 4(3): 39. DOI: [10.3390/vetsci4030039](https://doi.org/10.3390/vetsci4030039)
59. Sturm MC, Abazid A, and Stope MB. Tissue adhesion after surgical interventions. *Exp Ther Med.* 2025; 29(5): 1-9. DOI: [10.3892/etm.2025.12847](https://doi.org/10.3892/etm.2025.12847)
60. Davey AK, and Maher PJ. Surgical adhesions: A timely update, a great challenge for the future. *J Minim Invasive Gynecol.* 2007; 14(1): 15-22. DOI: [10.1016/j.jmig.2006.07.013](https://doi.org/10.1016/j.jmig.2006.07.013)
61. Ellison GW. Complications of gastrointestinal surgery in companion animals. *Vet Clin North Am Small Anim Pract.* 2011; 41(5): 915-934. DOI: [10.1016/j.cvsm.2011.05.006](https://doi.org/10.1016/j.cvsm.2011.05.006)
62. Holzman G, and Kleist TR, editors. *Surgical patient care for veterinary technicians and nurses.* 2nd ed. John Wiley & Sons, 2023. DOI: [10.1002/9781119760313](https://doi.org/10.1002/9781119760313)
63. Antar SA, Ashour NA, Marawan ME, and Al-Karmalawy AA. Fibrosis: Types, effects, markers, mechanisms for disease progression, and its relation with oxidative stress, immunity, and inflammation. *Int J Mol Sci.* 2023; 24(4): 4004. DOI: [10.3390/ijms24044004](https://doi.org/10.3390/ijms24044004)
64. Jin Z, Guan Y, Yu G, and Sun Y. Magnetic resonance imaging of postoperative fracture healing process without metal artifact: A preliminary report of a novel animal model. *Biomed Res Int.* 2016; 2016(1): 1429892. DOI: [10.1155/2016/1429892](https://doi.org/10.1155/2016/1429892)
65. Low D, Treharne R, and Rutherford S. Machine-learning prediction of postoperative complications after high tibial osteotomy for canine cranial cruciate ligament disease. *Vet Surg.* 2025; 54(7): 1286-1297. DOI: [10.1111/vsu.70007](https://doi.org/10.1111/vsu.70007)
66. Xue B, Li D, Lu C, King CR, Wildes T, and Avidan MS. Use of machine learning to develop and evaluate models using preoperative and intraoperative data to identify risks of postoperative complications. *JAMA Net Open.* 2021; 4(3): e212240. DOI: [10.1001/jamanetworkopen.2021.2240](https://doi.org/10.1001/jamanetworkopen.2021.2240)
67. Bouhali O, Bensmail H, Sheharyar A, David F, and Johnson JP. A review of radiomics and artificial intelligence and their application in veterinary diagnostic imaging. *Vet Sci.* 2022; 9(11): 620. DOI: [10.3390/vetsci9110620](https://doi.org/10.3390/vetsci9110620)
68. Tomaszewski MR, and Gillies RJ. The biological meaning of radiomic features. *Radiology.* 2021; 298(3): 505-516. DOI: [10.1148/radiol.2021202553](https://doi.org/10.1148/radiol.2021202553)
69. Rajgor A, Gill T, Aboagye E, Mill A, Rushton S, Obara B, et al. Radiomics from routine CT and PET/CT imaging in laryngeal squamous cell carcinoma: A systematic review with radiomics quality score assessment. *Cancers.* 2026; 18(2): 237. DOI: [10.3390/cancers18020237](https://doi.org/10.3390/cancers18020237)
70. Bonde A, Varadarajan KM, Bonde N, Troelsen A, Muratoglu OK, Malchau H, et al. Assessing the utility of deep neural networks in predicting postoperative surgical complications: A retrospective study. *Lancet Digit Health.* 2021; 3(8): 471-485. DOI: [10.1016/S2589-7500\(21\)00084-4](https://doi.org/10.1016/S2589-7500(21)00084-4)
71. Hussain SM, Brunetti A, Lucarelli G, Memeo R, Bevilacqua V, and Buongiorno D. Deep learning based image processing for robot assisted surgery: A systematic literature survey. *IEEE Access.* 2022; 10: 122627-122657. DOI: [10.1109/ACCESS.2022.3223704](https://doi.org/10.1109/ACCESS.2022.3223704)
72. Scholz AM, Bünger L, Kongsro J, Baulain U, and Mitchell AD. Non-invasive methods for the determination of body and carcass composition in livestock: Dual-energy X-ray absorptiometry, computed tomography, magnetic resonance imaging and ultrasound: Invited review. *Animal.* 2015; 9(7): 1250-1264. DOI: [10.1017/S1751731115000336](https://doi.org/10.1017/S1751731115000336)
73. Song Q, He X, Wang Y, Gao H, Tan L, and Ma J. Clinical validation of AI assisted animal ultrasound models for diagnosis of early liver trauma. *Sci Rep.* 2025; 15(1): 22513. DOI: [10.1038/s41598-025-91900-5](https://doi.org/10.1038/s41598-025-91900-5)
74. Leivaditis V, Maniatopoulos AA, Lausberg H, Mulita F, Papatriantafyllou A, Liolis E, et al. Artificial intelligence in thoracic surgery: A review bridging innovation and clinical practice for the next generation of surgical care. *J Clin Med.* 2025; 14(8): 2729. DOI: [10.3390/jcm14082729](https://doi.org/10.3390/jcm14082729)